

# A Survey on Automatic Detection of Diabetic Retinopathy Exudates from Retinal Fundus Images

Falguni Thakkar<sup>1</sup>, Rajvi Parikh<sup>2</sup>

Research Scholar, Department of Information Technology, G.H. Patel College of Engineering & Technology,  
Vallabh Vidyanagar<sup>1</sup>

Assistant Professor, Department of Information Technology, G.H. Patel College of Engineering & Technology,  
Vallabh Vidyanagar<sup>2</sup>

**Abstract:** Diabetic Retinopathy is the Leading cause of blindness in the ongoing life. It is the major problem in worldwide. Recent health studies estimates that 54 million American have diabetes and most of them don't know it. WHO reveal that 347 million people have this diabetes worldwide? As many as 25,000 people have lose their vision because of diabetic retinopathy every year. When the retina is damaged due to fluid leaks from blood vessels into the retina is the sign of diabetic retinopathy. In extreme cases, the patient will become blind. Damage to the tiny blood vessels in the retina due to diabetes is named as (DR) Diabetic Retinopathy. It is the diabetes for the person who having high blood sugar. Diabetic retinopathy can affect both the eyes of person without any pre sign or symptoms. But Proper screening for diabetic retinopathy will reduce the risk of blindness at earlier stage.

**Keywords:** Diabetic Retinopathy, Exudates, Retinal funds image.

## I. INTRODUCTION

“Diabetic retinopathy (DR) is the most common cause of blindness and vision defects in developed countries. Mainly There are two types of stage of diabetic retinopathy based on appearance of New blood vessels: Proliferative diabetic Retinopathy and Non-proliferative Diabetic retinopathy. Proliferative means to grow at a rapid rate by producing new cells or abnormal blood vessels in retina. It often occurs near the optic disk. It is classified as high or early Risk. When Non-proliferative means that the growth of abnormal new blood is not yet occurring. 50% Patients who have type-1 diabetes and around 10% people have type-2 diabetes so they require insulin to control the diseases and is low among those who do not.

**Diabetic Retinopathy has four stages:**

- (1) Mild non-proliferative retinopathy:** At this early stage, Micro aneurysms, i.e., small swellings in the tiny blood vessels of the retina will be formed in this stage.
- (2) Moderate non-proliferative retinopathy:** As the disease progresses, some blood vessels which are responsible for nourish the retina become blocked.
- (3) Severe non-proliferative retinopathy:** At this stage, Many more blood vessels become blocked, which disrupts the blood supply that nourishes the retina. The damaged retina then signals the body to produce new blood vessels.
- (4) Proliferative retinopathy:** At this advanced stage, signals sent by the retina that trigger the development of

new blood vessels that grow in the retina and the vitreous, which is a transparent gel that fills the interior part of the eye. Because these new blood vessels are abnormal and fragile, they can rupture and bleed, causing hemorrhages in the retina. Scar tissue can develop and can tug at the retina, causing further damage or even retinal detachment. [5]

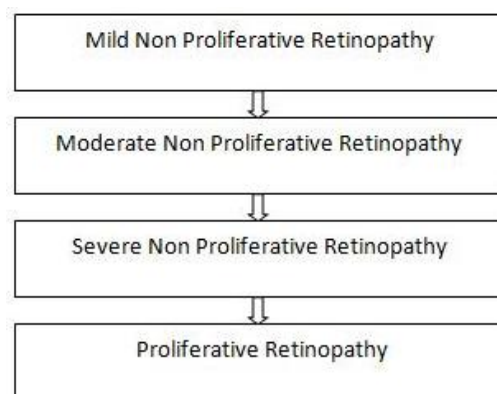


Fig. 1 Four Stages of Diabetic Retinopathy

**Diabetic Retinopathy features:**

The person who have diabetic retinopathy has to detect the number of fundus image features like Micro aneurysms(MA), fovea, microvascular abnormalities, hemorrhages, cotton-wool spots, Exudates, Retinal blood vessels, optic disc, optic disc boundary and macula that we can predicted using different image processing techniques.

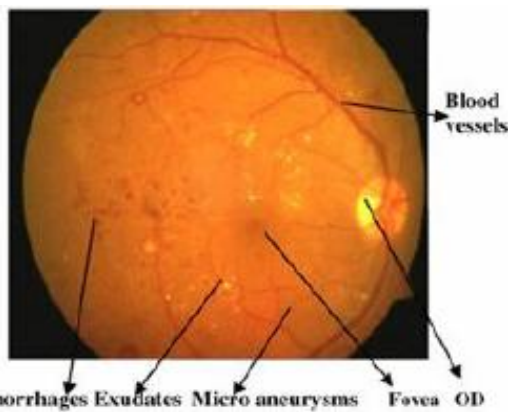


Fig.2 Retina lesions associated with diabetic Retinopathy

## II. REVIEW OF METHODS

In year 2012, Vesna Zeljković, Claude Tameze, Ventzeslav Valev performed work, “Classification Algorithm of Retina Images of Diabetic Patients Based on Exudates Detection”. [1] Author presents he automated retina image classification algorithm is use to detect exudates from fundus iamge and classification of diabetes.this algorithm mainly focus on contrast enhancement and emphasis intensity of exudates region.

In year 2007, Clara I. S´anchez, Roberto Hornero, Mar´ia I. L´opez b, Mateo Aboy, Jes´us Poza, Daniel Ab´asolo has performed work, “A novel automatic image processing algorithm for detection of hard exudates based on retinal image analysis” The proposed algorithm is based on Fisher’s linear discriminant analysis and makes use of colour information to perform the classification of retinal exudates. It implement using 4 stages: (1) Image preprocessing and enhancement(2) Feature extraction, (3) classification (4) Postprocessing.[2]

In year 2008, Akara Sopharak a,\*, Bunyarit Uyyanonvara a,1, Sarah Barmanb, Thomas H. Williamson, “Automatic detection of diabetic retinopathy exudates from non-dilated retinal images using mathematical morphology methods” here. [3] They investigates and proposes a set of optimally adjusted morphological operators to be used for exudate detection on diabetic retinopathy patients’ non-dilated pupil and low-contrast images.

In year 2009, Daniel Welfera, Jacob Scharcanskia,\*, Diane RuscheMarinhob, “A coarse-to-fine strategy for automatically detecting exudates in color eye fundus images” author proposed mathematical morphology method for detecting exudates from fundus image of diabetic patient.[4]

In year 2009, Clara I. S´anchez a,b,\*, Mar´ia Garc´ia a, Agust´ın Mayo c, Mar´ia I. L´opez b, Roberto Hornero, “Retinal image analysis based on mixture models to detect hard exudates”, The proposed algorithm is based on mixture models to dynamically threshold the images in order to separate exudates from background.. A postprocessing technique, based on edge detection, is applied to distinguish hard exudates from cotton wool spots

and other artefacts.[5]

In year 2011, C.JayaKumaria ,R.Maruthib a\*, “Detection of Hard Exudates in Color Fundus Images of the Human Retina”, For Detect automatic exudates they present state of art image processing technique . [6] After the contrast adaptive histogram equalization as pre- processing stage, contextual clustering algorithms have been applied to segment the exudates.

In year 2011, Luca Giancardo ,Fabrice Meriaudeau , Thomas P. Karnowski , Yaqin Li , Seema Garg d, Kenneth W. Tobin Jr. e, Edward Chaum, “Exudate-based diabetic macular edema detection in fundus images using publicly available datasets” In this work, Author introduce a new methodology for diagnosis of DME using a novel set of features based on colour, wavelet decomposition and automatic lesion segmentation.

In year 2012, Doaa Youssef, Nahed H. Solouma\*, “Accurate detection of blood vessels improves the detection of exudates in color fundus images”, The given method starts with an edge detection algorithm which results in a over segmented image. Then the new feature-based algorithm can be used to accurately detect the blood vessels.[8] Which considers the characteristics of a retinal blood vessel such as its width range, intensities and orientations for the purpose of selective segmentation. And using morphological reconstruction method estimate the exudates. It increases the sensitivity and specificity of exudates detection to 80% and 100% respectively.

In year 2013, SynaSreng, Noppadol Maneerat, Don Isarakorn, BunditPasaya, lun-ichi Takada, Ronakorn Panjaphongse, Ruttikorn Varakulsiripunth, “ Automatic Exudate Extraction for Early Detection of Diabetic Retinopathy”, First preprocess to improve the quality of image ,then by combination of 3 methods; image binarization, Region Of Interest (ROI) based segmentation and Morphological Reconstruction (MR). Then exudates are detected by maximum entropy thresholding to filter out the bright pixels from the result of OD region eliminated and detect exudates. In year 2013, Archana.G, Avinaya.V, Chegireddy Keerthi, Gayathri Shivaram and S.Vasanthi, “ Abnormality Detection and Its Severity Classification in Retinal Images”, First eliminate the non uniform illumination to enhance the brightness of image.[10] A novel abnormality detection method is illustrated which classifies the retinal images as normal or abnormal based on the features obtained from the image. In year 2013, Nidhal K. El Abbadi, Enas Hamood Al- Saadi, “ Automatic Detection of Exudates in Retinal Images”, Author introduced new methods to element the optic disk and removes the main part that makes confusion with exudates.

In year 2013- Anitha Somasundaram, Janardhana Prabhu, “ Detection of Exudates for the Diagnosis of Diabetic Retinopathy”, an automated algorithm has demonstrated to detect and localize the presence of exudates. Then,

Mask Technique and Score Computation technique is used for segmenting the exudates.

In year 2012, NayomiGeethanjaliRanamuka, RavindaGayan N Meegama, "Detection of hard exudates from diabetic retinopathy images using fuzzy logic", [13]. Mathematical morphology is used to detect exudates then an adaptive fuzzy logic algorithm that uses values in the RGB colour space of retinal image to form fuzzy sets and membership functions.

In year 2013, Anitha Mohan, K. Moorthy, "Early Detection of Diabetic Retinopathy Edema using FCM", Saturation Value which help to extract the accurate The author used median filter to reduce noise, Hue region, Fuzzy c mean

method of clustering for pattern recognition and at last detect exudates parts.

In year 2013, Wei Bu, Xiangqian Wu, Xiang Chen, Baisheng Dai, YalinZheng, "Hierarchical Detection of Hard Exudates in Color Retinal Images", Here a novel method is presented to detect HEs automatically from fundus image. It has 2 methods: In coarse level. combining histogram segmentation with morphological reconstruction to detect HE and in fine level SVM model to classify HEs and non-HEs. The sensitivity of 94.7% and a positive predictive value of 90.0%.

In year 2015, Poonam M. Rokade, Ramesh R.Manza, "Automatic Detection of Hard Exudates in Retinal Images

Sr No.	Algorithm	Pros	Cons
1	Cost effective algorithm [1]	The proposed algorithm focuses on contrast enhancement and emphasis of the intensity of the isolated exudates regions. The performance of the algorithm is fast and efficient due to the applied mathematical modeling.	The proposed algorithm fails to correctly classify up to 4% of the observed retina images due to the changes in the appearance of retinal fundus image typically encountered in clinical environments.
2	A novel automatic image processing algorithm [2]	The proposed algorithm does not require user initialization and is robust to the changes in the appearance of retinal fundus images.	A limitation of this approach is that it cannot represent the colour of all the exudates found in images.
3	Exudate detection techniques based on mathematical morphology [3]	We based our work on this technique because it is very fast and requires lower computing power.	One main weakness of the algorithm arises from the fact that the algorithm depends on other tasks, namely, the detection of the optic disc, and vessel removal.
4	A mathematical morphology method [4]	It is better than other methods and potentially can be applicable in practice.	our method is not suitable for detecting exudates in retinal images that contains normal macular reflection
5	Mixture models (MMs) [5]	The proposed algorithm is more robust in that potential outliers do not contribute to the threshold selection, setting a more accurate value for all the images.	Using mixture models, we leave out the existence of spatial correlation between observations at neighboring pixels. .
6	Contextual Clustering algorithm [6]	It tried out here is that a recurrent neural network has been used to classify the lesion which produced very good result.	The use of other networks, any other image processing algorithms or any other symptoms of diabetic retinopathy may be detected as the direction of future work.
7	edge detection algorithms ,blood vessel detection algorithm [8]	This algorithm can work properly with lower quality retinal images and images containing hemorrhage and exudates together.	We intend to extend our proposed method to help improve the detection of hemorrhage
8	Classification of hard exudates using fuzzy logic [13]	The strength of this approach is the ability to determine whether each exudate is hard exudate or not.	the work needs to be improved to detect exudate pixels having very low intensity values.
9	A novel method :two stages: coarse level and fine level.[15]	The experimental results showed that our method can detect HEs effectively and distinguish HEs accurately from other interferences.	We intend to extend the proposed method to segment CWS and build an integrated diagnosis system of DR which can detect dark lesion such as microaneurysm and hemorrhage.
10	Mask Technique and Score Computation technique [12]	The proposed system is a very simple technique which enables the ophthalmologists to detect exudates with very less inspection time.	Not given

Using Haar Wavelet Transform”, First preprocessing steps have been applied for exudates probability map and then used Hard Wavelet Transform for early detection of DR. In year 2014, Morium Akter, Atiqur Rahman, A. K. M. Kamrul Islam, “An improved method of automatic exudates detection in retinal image”, The input color fundus image is converted in to gray scale then median filter method is used.[16] In foreground image optic disk and exudates are remain, so optic disk is removed by erosion and dilation and exudates are detected by and operation between dilated image and foreground image. In year 2015, B. Srilatha, Dr. V. Malleswararao, “Extraction of Blood Vessels and Exudates from Retinal Images using Image processing Algorithms”, In this paper first step is median filter and for blood vessels and exudates extraction is done by kirsch algorithm and fuzzy clustering algorithm.[18] In year 2013, Mahendran Gandhi et.al. “Diagnosis of Diabetic Retinopathy Using Morphological Process and SVM Classifier”, First RGB to gray scale image conversation is done than apply preprocessing technique and morphological operation are applied to detect exudates from image. then SVM is used to classify images in to moderate or severe. In year 2012, Luca Giancardo, Fabrice Meriaudeau, Thomas P. Karnowski, Yaqin Li, Seema Garg, Kenneth W. Tobin Jr., Edward Chaum, “Exudate-based diabetic macular edema detection in fundus images using publicly available datasets”, Using best feature selection based on color, wavelet decomposition and automatic lesion segmentation and classify single feature vector for every image through the presence of exudation. In year 2012, Atul Kumar, Abhishek Kumar Gaur, Manish Srivastava, A Segment based Technique for detecting Exudate from Retinal Fundus image”, Preprocessing to enhance the image, morphological operation to locate the optic disk from the fundus image then SVM classifier to detect exudates which compared with expert hand-drawn ground-truths.[21] It achieved sensitivity and specificity as 97.1% and 98.3% respectively. In year 2009, Keerthi Ram and Jayanthi Sivaswamy, “Multi-space clustering for segmentation of Exudates in Retinal Colour Photographs”, They proposed clustering based method to segment exudates and extract the multi space and color space features. They consider processing time factor and achieved 89.7% accuracy and 87% positive prediction values. In year 2012, C. Jaya Kumari, R. Maruthi, “Detection of Hard Exudates in Color Fundus Images of the Human Retina”, After preprocessing a contextual clustering algorithm is used to detect hard exudates. Features which extract from segmented image are the standard deviation, mean, intensity, edgestrength and compactness which given as inputs to Echo State Neural Network (ESNN) to discriminate between the normal and pathological image.

### III. CONCLUSION

This survey paper is useful for the further researchers who are interested in automated detection of hard exudates in diabetic retinopathy detection and help them to get more idea about which work has been done and which different algorithms has been used to detect DR in earlier stage.

### REFERENCES

- [1] Vesna Zeljković<sup>1</sup>, Milena Bojic<sup>2</sup>, Claude Tameze<sup>3</sup>, Ventseslav Valev<sup>4</sup>, “Classification Algorithm of Retina Images of Diabetic Patients Based on Exudates Detection”, IEEE-2012.
- [2] Clara I. Sánchez, Roberto Hornero, María I. López b, Mateo Aboy, Jesús Poza, Daniel Abásolo has performed work, “A novel automatic image processing algorithm for detection of hard exudates based on retinal image analysis”, Elsevier-2007.
- [3] Akara Sopharak, Bunyarit Uyyanonvara, Sarah Barmanb, Thomas H. Williamson, “Automatic detection of diabetic retinopathy exudates from non-dilated retinal images using mathematical morphology methods”, Elsevier-2008.
- [4] Daniel Welfera, Jacob Scharcanskia., Diane Rusche Marin hob, “A coarse-to-fine strategy for automatically detecting exudates in color eye fundus images”, Elsevier-2009.
- [5] Clara I. Sánchez a,b,\*, María García a, Agustín Mayo c, María I. López b, Roberto Hornero, “Retinal image analysis based on mixture C. Jaya Kumaria, R. Maruthib, “Detection of Hard Exudates in Color Fundus Images of the Human Retina”, Elsevier Ltd.-2011.
- [7] Luca Giancardo, Fabrice Meriaudeau, Thomas P. Karnowski, Yaqin Li, Seema Garg d, Kenneth W. Tobin Jr. e, Edward Chaum, “Exudate-based diabetic macular edema detection in fundus images using publicly available datasets”, 2011 Elsevier.
- [8] Doaa Youssef, Nahed H. Solouma\*, “Accurate detection of blood vessels improves the detection of exudates in color fundus images”, 2012 Elsevier Ireland Ltd. [9] Shiblee Sadik and Le Gruenwald, “Research Issues in Outlier Detection for Data Streams”, SIGKDD Explorations, Volume 15, Issue 1.
- [9] Syna Sreng, Noppadol Maneerat, Don Isarakorn, Bundit Pasaya, lun-ichi Takada, Ronakorn Panjaphongse, Ruttikorn Varakulsiripunth, “Automatic Exudate Extraction for Early Detection of Diabetic Retinopathy”, IEEE-2013.
- [10] Archana G. Avinaya V, Chegireddy Keerthi, Gayathri Shivaram and S. Vasanthi, “Abnormality Detection and Its Severity Classification in Retinal Images”, IJREAT-2013.
- [11] Nidhal K. El Abbadi, Enas Hamood Al-Saadi, “Automatic Detection of Exudates in Retinal Images”, IJCSI-March 2013..
- [12] Anitha Somasundaram, Janardhana Prabhu, “Detection of Exudate for the Diagnosis of Diabetic Retinopathy”, International Journal of Innovation and Applied Studies, March-2013.
- [13] Nayomi Geethanjali Ranamuka, Ravinda Gayan N Meegama, “Detection of hard exudates from diabetic retinopathy images using fuzzy logic”, IET Image Process., 2013.
- [14] Anitha Mohan, K. Moorthy, “Early Detection of Diabetic Retinopathy Edema using FCM”, IJSR-2013.
- [15] Wei Bu, Xiangqian Wu, Xiang Chen, Baisheng Dai, Yalin Zheng, “Hierarchical Detection of Hard Exudates in Color Retinal Images”, JOURNAL OF SOFTWARE, VOL. 8, NO. 11, NOVEMBER 2013.
- [16] Morium Akter, Atiqur Rahman, A.K.M. Kamrul Islam, “An improved method of automatic exudates detection in retinal image” IJIREICE-2014.
- [17] Poonam M. Rokade, Ramesh R. Manza, “Automatic Detection of Hard Exudates in Retinal Images Using Haar Wavelet Transform”, IJAIEEM-2015.
- [18] B. Srilatha, Dr. V. Malleswararao, “Extraction of Blood Vessels and Exudates Retinal Images using Image processing Algorithms”, IJSER-2015.
- [19] Mahendran Gandhi et.al. “Diagnosis of Diabetic Retinopathy Using Morphological Process and SVM Classifier” IEEE International conference on Communication and Signal Processing, April 3-5, 2013, India.
- [20] Luca Giancardo, Fabrice Meriaudeau, Thomas P. Karnowski, Yaqin Li, Seema Garg, Kenneth W. Tobin Jr., Edward Chaum, “Exudate-based diabetic macular edema detection in fundus images using publicly available datasets”, Medical Image Analysis, Vol. 16, No. 1, pp. 216–226-2012.
- [21] Atul Kumar, Abhishek Kumar Gaur, Manish Srivastava, (2012), A Segment based Technique for detecting Exudate from Retinal Fundus image”, Procedia Technology, Vol. 6, pp. 1–9.
- [22] Keerthi Ram and Jayanthi Sivaswamy, “Multi-space clustering for segmentation of Exudates in Retinal Colour Photographs,” 31st Annual International Conference of the IEEE EMBS, USA, pp 1437-1440, September 2009.
- [23] C. Jaya Kumari, R. Maruthi, “Detection of Hard Exudates in Color Fundus Images of the Human Retina”, Procedia Engineering, Vol. 30, pp. 297–302-2012.
- [24] Swati Gupta, A.M. Karandikar, “A Survey On Automatic Detection of Diabetic Retinopathy”, International Journal of Research in IT, Management and Engineering, January 2015