

# Lenke's Scoliosis Classification Using Image Processing Techniques

Anitha H

Department of Electronics and Communication Engineering, Manipal Institute of Technology,  
Manipal University Manipal, India

**Abstract:** One of major spinal deformities is scoliosis and is diagnosed using posterior-anterior radiograph. The diagnosis and subsequent treatment of the problem depends on the type of scoliosis. Classification by radiograph measure is used to determine the extent of arthrodesis. Although the King's classification technique has been used more widely because of its simplicity; it is not as effective a method of classification as the Lenke's classification because of low intra observer and inter-observer reliability. Various aspects of the process to automate the efficient classification of Scoliosis radiographs on the basis of Lenke's system using image processing techniques is presented in this paper. Effective image segmentation techniques are used to extract the spinal boundary and inter-vertebral boundaries with help of different image processing software. These shall, in turn, be used in a formulated algorithm to determine and classify the type of scoliosis seen in a radiograph, based on Lenke's classification system. Objective measurement by the proposed method can eliminate some sources of inter and intra observer error in classification of scoliosis.

**Keywords:** Scoliosis, Lenke's Classification, Scoliosis classificaion

## I. INTRODUCTION

Scoliosis is a complex deformity of the spinal column characterized by lateral shift of spinal curve in frontal plane. Although it is a complex three-dimensional deformity, on an X-ray, viewed from the rear, the spine of an individual with scoliosis may look like an "S" or a "C" than a straight line. Scoliosis is typically classified as either congenital (caused by vertebral anomalies present at birth), idiopathic (cause unknown, sub-classified as infantile, juvenile, adolescent, or adult, according to when onset occurred), or neuromuscular (having developed as a secondary symptom of another condition, such as spinal bifida, cerebral palsy, spinal muscular atrophy, or physical trauma).

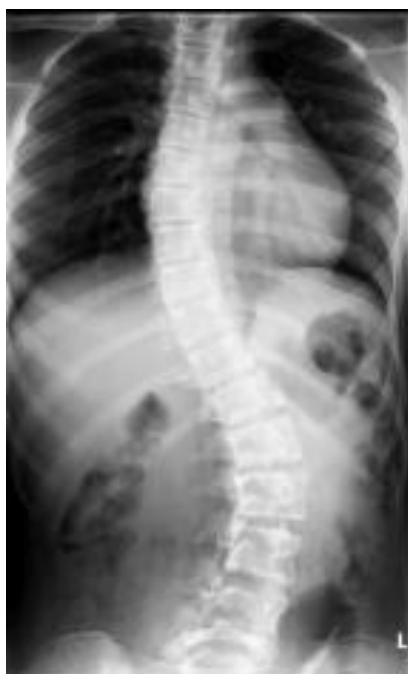

Fig 1: Scoliosis P.A. Radiograph

Scoliosis classification scheme is useful for guiding the treatment and testing the clinical outcome. During diagnosis it is often confusing to define the degree of curve. To avoid such confusion classification procedure has been adopted. The curves are counted and classified into single, double and triple based on the apex number.

### Classification of Scoliosis:

Classification is used to facilitate the objective assessment for different examiners, thus making result as uniform and comparable as possible. There are currently two recognized classification methods, viz., King Classification [6] and Lenke's classification [7]. King classification has 5 patterns and Lenke's has 42 potential patterns.

A good classification system has to include different types of curves and should be a guide to surgical planning. Of the two classification techniques, the latter one i.e. Lenke's classification scheme is being brought into use more often these days. This is mostly because of the lack of inter-observer and intra-observer reliability obtained from King's classification. The features of Lenke's classification scheme which make it more favourable, reliable, comprehensive and hence more efficient [4].

In a paper published in the journal of joint and bone surgery in 2001, Rd. Lawrence G. Lenke et al [1] spoke about an investigation that a team of technicians, doctors and surgeons carried out in the Barnes-Jewish Hospital, Washington University, St. Louis, Missouri. Lenke adopted a rigorous form of classification for scoliosis radiographs as shown in Fig 2. The curve apex is defined in various ways for localization purposes like upper thoracic localization, thoracic localization and lumbar localization.

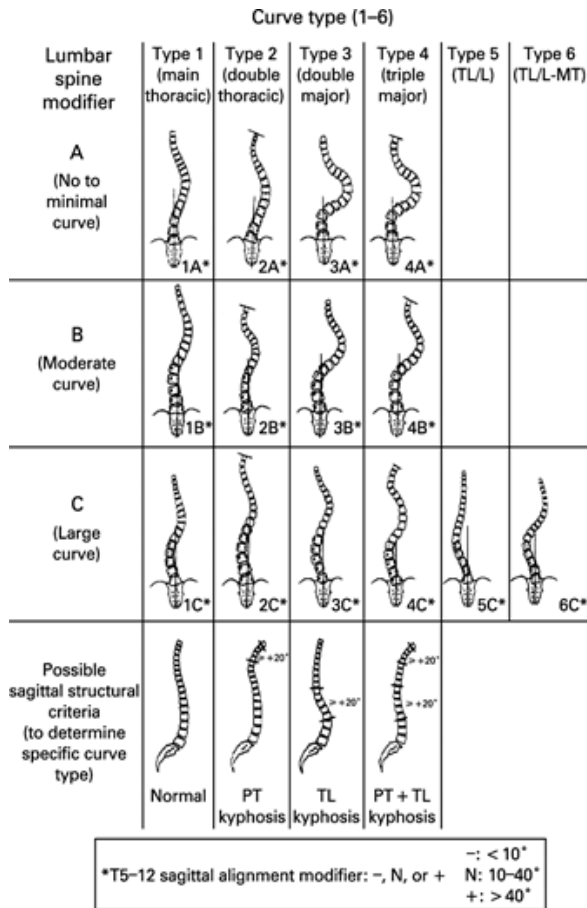


Fig 2: Lenke's classification [3]

The team developed a new system for classification of adolescent idiopathic scoliosis, on the basis of radiographs made in the coronal and sagittal planes, which could be used to determine the appropriate vertebral levels to be included in an arthrodesis. Two groups of surgeons tested this new classification, and the results were used to calculate inter-observer and intra observer reliability. The results showed substantial improvements in the reliability and efficiency which was mostly attributed to the fact that the new classification system developed by Lenke et al did in fact, take into considerations a majority of factors other than deviation of the spine from the CSVL into consideration.

Lenke's classification can be suitably applied to automate the process of classification. This automation process involves Cobb angle estimation of different sections of the spine. Once such angles are found, the values are used to find the curve type of the scoliosis spine using a suitable algorithm or decision rule.

## II. BACKGROUND

Various scientific papers pertaining to the given subject were read in detail and a general idea of the classification techniques and tools are gathered. Among these the work in "Computer-aided Lenke classification of scoliosis spines" by Meghan et al [2] (World academy of Science, Engineering and Technology) was used to have an understanding of how the curve types are defined while classifying a PA radiograph. The paper also discuss with

basic attempts at developing a computer algorithm to implement the same. Additionally the work of Lawrence G. Lenke et al [1] was studied to have a better understanding of the evolution of the Lenke's method of classification and further reading of their works in "Intra-observer and Inter-observer Reliability of the Classification of Adolescent Idiopathic Scoliosis" [3] was studied to have a basic idea of how the improvement in reliability is brought about. Now, in this section we shall go through in detail of how exactly the classification algorithms work to comprehensively classify the scoliosis radiographs. Additionally the work "On the Geometric Characterization of the Lenke Classification Scheme for Idiopathic Scoliosis"[5] presented by Dean A. Entrekin as a thesis to the faculty of the Virginia Polytechnic Institute and State University and Wake Forest University was used to chalk out the exact finer details of maker vertebrae to be used for finding Cobb angles of different sections of the spine.

This work involves a number of steps which are undertaken to make it possible to automate most of the process of classification of scoliosis spines in the PA radiographs, thus, minimizing necessity of human intervention.

## III. PROPOSED WORK

The initial part involves working on algorithms for segmentation of the given input image i.e. the scoliosis PA radiograph so as to have only the Region of Interest (ROI) i.e. the vertebral column or spine among the ribs and other tissues that are visible in the radiograph. Further, the image is enhanced using various image processing techniques so as to extract certain morphological features that can later on be used to calculate the various parameters used to classify the scoliosis radiographs in Lenke's classification scheme. In the subsequent sections we shall see how the process of determination of the curve-type has been automated with minimal human intervention. The entire process and the associated algorithms have been implemented using MatLab and details are available in our previous work [8]. The ROI in the given scoliosis radiograph is found to be the spinal region of the rib cage. Hence, the primary portion of the work involves segregation of this ROI from the image, for which the following algorithm has been used.

### Algorithm:

1. The given image is grey scaled, if not already in greyscale.
2. Thresholding is done to remove pixels with lower intensity. A new image is thus generated.
3. Fourier transform, axis adjustment, row-wise and user-fed thresholding to generate a modified row of pixels.
4. The modified pixel values from the previous step are then assimilated to form an intermediate output image, which contains only the ROI i.e. the spinal region.

Step1: Sobel mask is used to detect edges and a convolution of a suitable mask with the image containing the edges is done to calculate connected components.

Step2: Median filtering is used with a Gaussian filter with suitable values of size and sigma to reduce or expand the boundary of the output of the filtering process.

Step3: The user defined functions “boundaries” is used along with in built functions such as “BWmorph” and “BWfill” to extract a filled mask for the spinal ROI.

Step4: The resultant image boundary traced for the ROI.

The image thus obtained has only the spine. Some pixels within the ROI might have been lost because of the empirical value taken for sigma and size used while filtering using the Gaussian filters.

For most of the cases, it was found that a value of size of the filter around 50 and a sigma around 60 produced good results without significant loss of data. It is used to determine the Cobb angles of different sections of the spine using some manual interference, in the form of selecting points on the vertebrae along whose end-plates the angles have to be found.

To remove any ambiguity while selecting such points, it is necessary to enhance the contrast of the image and sharpen it if possible to a better degree, so that the individual vertebral end plates are well segmented and clearly visible –clear enough to make sure that the only bit of manual intervention required in this process is as error-free as possible.

Among the many techniques available to improve the clarity, it was found that if the brightness and the shadows in the image could be strengthened i.e. the contrast could be improved; our purpose will be well served. The process of adaptive histogram equalization was used with this goal.

Adaptive histogram equalization is a computer image processing technique used to improve contrast in images. It differs from ordinary histogram equalization in the respect that the adaptive method computes several histograms, each corresponding to a distinct section of the image, and uses them to redistribute the lightness values of the image. It is therefore suitable for improving the local contrast of an image and bringing out more detail.

Also it was seen that some amount of sharpening using a GUI developed using MatLab could also be put to use here, although this sharpening is not exactly compulsory.

#### Determination of Cobb angles and curve type:

Vertebral end-plates are involved in the calculation of the Cobb angle. Three such Cobb angles – one each for Proximal Thoracic (PT), Main Thoracic (MT) and Thoracolumbar/Lumbar (TL) regions of the spine are thus determined using simple coordinate geometry identities.

A sample of how a Cobb angle is determined is shown in Fig 3.

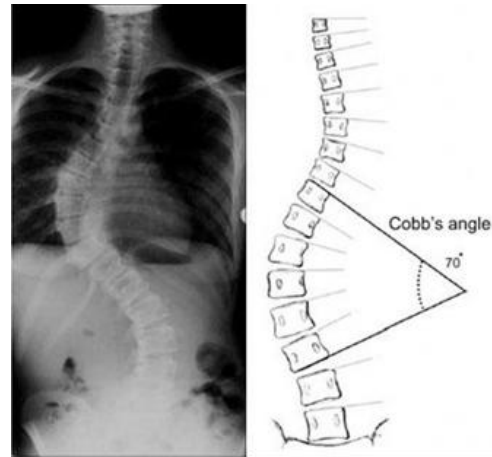


Fig 3: Cobb angle calculated for the Main thoracic region

Now, a suitable algorithm is used to determine the curve type in Lenke's classification method. After the initial literature survey, the algorithm described in the works of Meghzani et al [2] was found to be best suited for our purpose. The same has been shown in Fig 3.

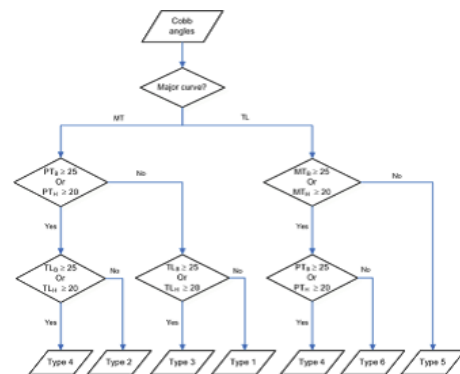


Fig 4: Algorithm to determine curve-type[2]

#### IV. EXPERIMENTAL RESULTS

The outputs were found to have been conclusive at segmenting out the spinal region. These were then used to improve the contrast using several techniques including the process of adaptive histogram equalization and image sharpening using a GUI. Another set of algorithms were used to derive the Cobb angles in different sections of the spine defined by user-selected sets of vertebral end-plates. Further, algorithms were defined and implemented to calculate the curve type for the given sets of co-ordinates selected by the user. The adopted method was found to be of much use as the computer-aided automatic classification was successful.

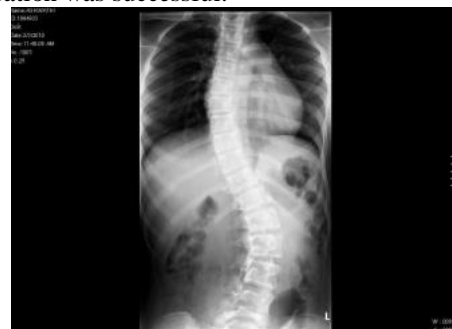

Fig 5: Initial input image

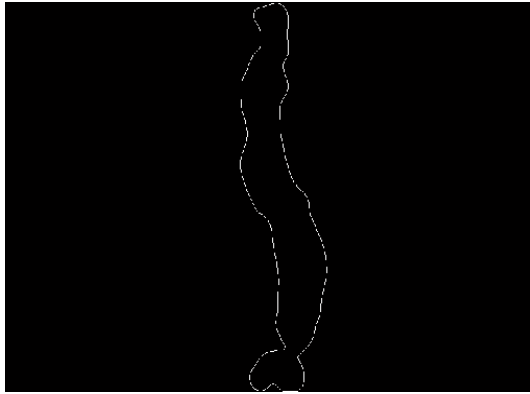


Fig 6: Image with boundary traced

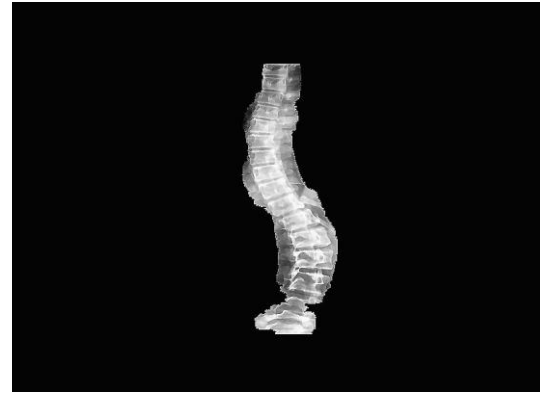


Fig 10: Image after sharpening




Fig 7: Image with boundary filled with 1's

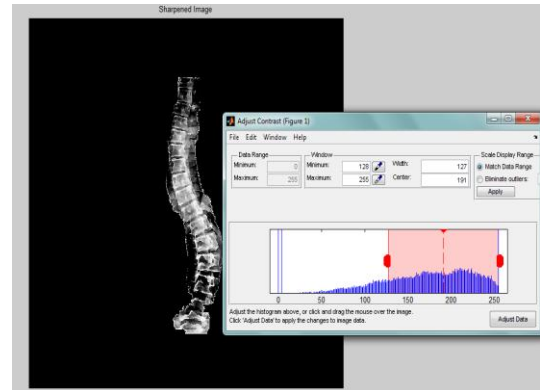


Fig 11 Use of GUI to improve and adjust contrast and sharpen the image.

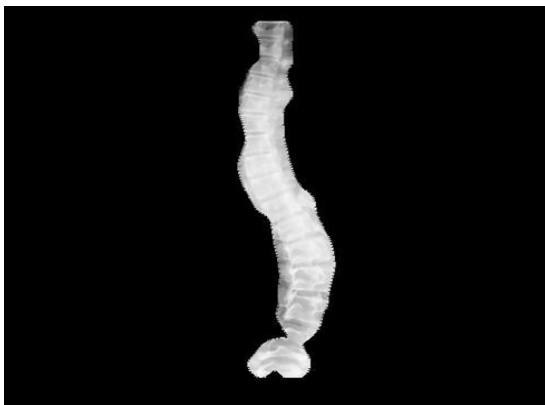

Fig 8: Superimposition of fig4.4 with original image

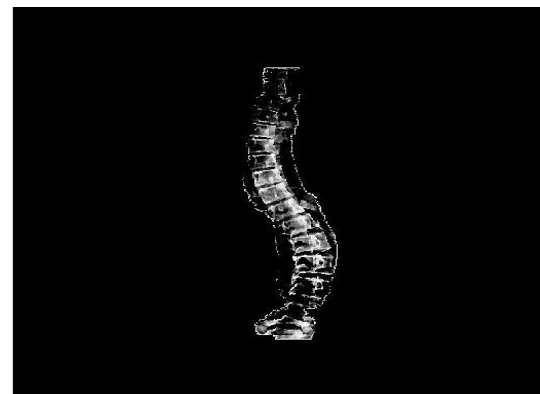


Fig 12: Sample image derived after adjusting the contrast and sharpening. Notice the clarity of the vertebral end plates in the main thoracic segment.

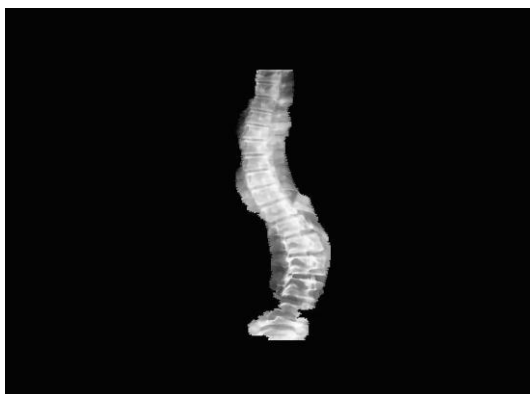

Fig 9: Image with improved values of Inputs to Median Filter. Contrast improved by Adaptive Histogram Equalization

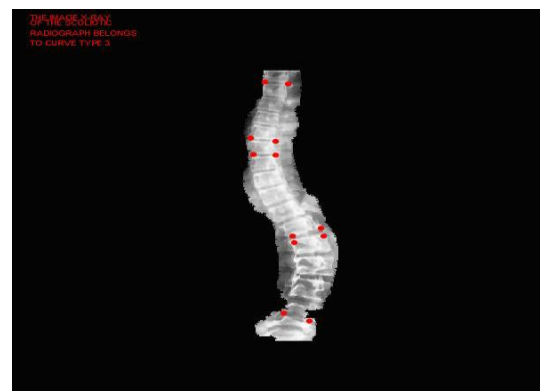

Fig 13: Final Image with Cure-type.

## V. CONCLUSION

The experimental result depicts that it has been possible to automate the process of classification of scoliosis PA radiographs using image processing techniques successfully. This was carried out with minimal human intervention, when the image in question has been processed suitably so as to have distinct spinal and intervertebral boundaries visible. The successful calculation of Cobb angles which, in turn, helped in accurate determination of curve type according to Lenke's classification system, thus concludes efficiency of the proposed work. The process of determination of curve type was done with minimal human intervention, when the image in question has been processed suitably so as to have distinct spinal and intervertebral boundaries visible. The successful calculation of Cobb angles which, in turn, helped in accurate determination of curve type according to Lenke's classification system, thus concludes with much success.

## REFERENCES

- [1] Lawrence G. Lenke et al, "Adolescent Idiopathic Scoliosis –A new classification to determine the extent of Spinal Arthrodesis", *Journal of Bone and Joint Surgery*, volume-1169, 2001
- [2] Neila Meghan, Philippe Phan et al, "Computer-aided Lenke classification of scoliosis spines", *World academy of Science, Engineering and Technology*, volume- 53, 2009
- [3] Ian A. F. Stokes, PhD, and David D. Aronsson, MD, "Identifying Sources of Variability in Scoliosis Classification Using a Rule Based Automated Algorithm", *SPINE Volume 27, Number 24*, pp 2801–2805, ©2002, Lippincott Williams & Wilkins, Inc.
- [4] Lawrence G. Lenke et al, "Intra-observer and Inter-observer Reliability of the Classification of Adolescent Idiopathic Scoliosis", *Journal of Bone and Joint Surgery*, volume-80:1097-1106-1198, 1998-99
- [5] Dean A. Entrekin, "Thesis on the Geometric Characterization of the Lenke Classification Scheme for Idiopathic Scoliosis", Thesis submitted to the faculty of the Virginia Polytechnic Institute and State University and Wake Forest University, May 21st 2004
- [6] P. Parisini et al, "Selective thoracic surgery in the Lenke type 1A: King III and King IV type curves", *European Spine Journal*, Volume: 18 (Suppl 1):S82–S88, 2009
- [7] Luc Duong, Farida Cheriet, and Hubert Labelle, "Automatic Detection of Scoliosis Curves in Posteroanterior Radiographs", *IEEE transactions on Biomedical Engineering*, volume-57, no. 5, May 2010
- [8] Anitha H and Karunakar A K, "Reliable and Reproducible Classification System for Scoliotic Radiograph using Image Processing Techniques", *Springer Journal of Medical Systems*, July 2014 DOI: 10.1007/s10916-014-0124-z